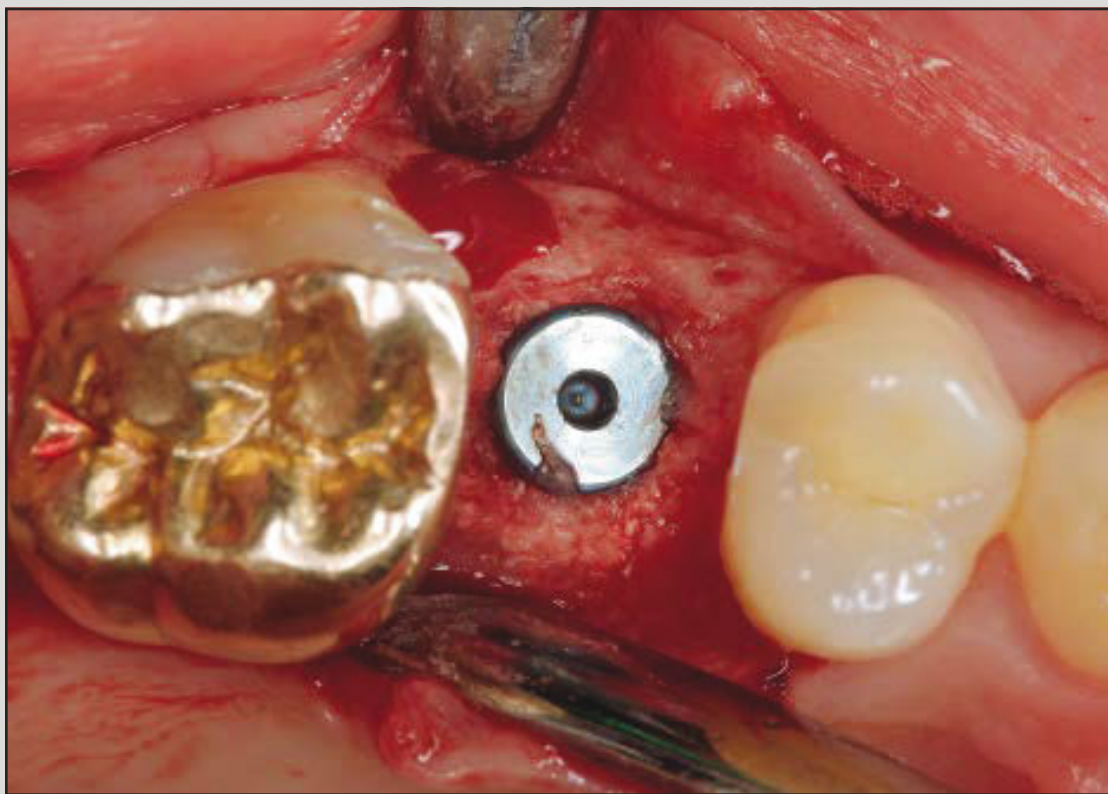
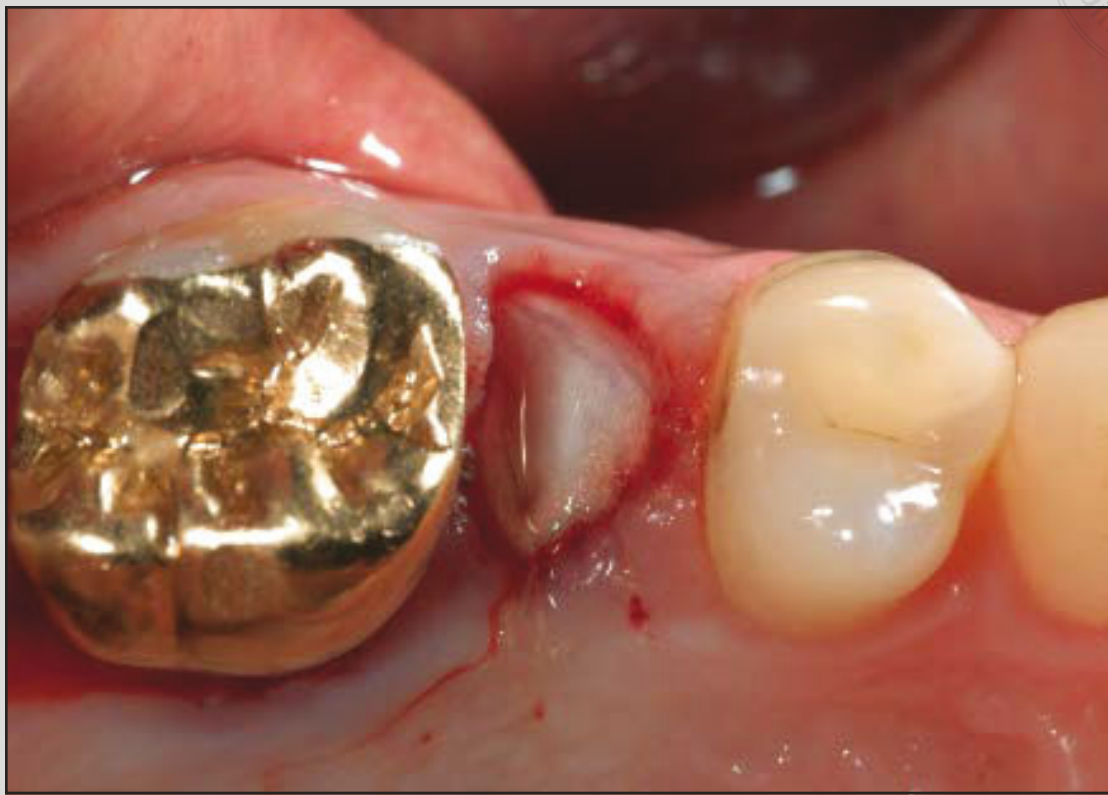
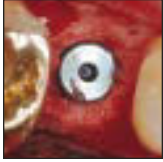Dimensional Evaluation of Different Ridge Preservation Techniques: A Randomized Clinical Study



Stefan Fickl, Priv-Doz Dr Med Dent¹
 Kai Fischer, Dr Med Dent²/Nicole Petersen³
 Arndt Happe, Priv-Doz Dr Med Dent⁴
 Markus Schlee, Priv-Doz Dr Med Dent⁵
 Ulrich Schlagenhaut, Prof Dr Med Dent⁶
 Moritz Kebschull, Priv-Doz Dr Med Dent⁷

The objective of this study was to quantitatively determine ridge contour changes after different alveolar ridge preservation techniques. An initial total of 40 patients provided a final total of 35 single-gap extraction sites. After tooth removal, the socket was subjected to one of four treatment modalities: placement of a deproteinized bovine bone mineral (DBBM; Endobon) covered with a soft tissue punch from the palate (Tx1); placement of DBBM without soft tissue punch (Tx2); placement of an adsorbable collagen membrane (Osseoguard) covering the DBBM (Tx3); and no additional treatment (control). Silicone impressions were obtained before and 6 months after tooth extraction for quantitative-volumetric evaluation on stone cast models. Bone quality and need for further bone augmentation were also noted. Tx1 and Tx3 resulted in significantly less bucco-oral tissue loss when compared to Tx2 and the control group. Premolar teeth and teeth extracted for traumatic reasons revealed significantly less tissue loss. Using barrier membranes or soft tissue punches in addition to placement of DBBM seems to be advantageous to limit bucco-oral tissue atrophy. The clinical benefit, however, is still questionable. Int J Periodontics Restorative Dent 2017;37:403–410. doi: 10.11607/prd.2629

¹Associate Professor, Department of Periodontology, Julius-Maximilians-University, Würzburg, Germany.

²Assistant Professor, Unit of Periodontology, University Witten/Herdecke Witten, Germany; Private Practice, Würzburg, Germany.

³Assistant Professor, Department of Periodontology, Julius-Maximilians-University, Würzburg, Germany.

⁴Associate Professor, Department of Oral and Maxillofacial Plastic Surgery, University of Cologne, Cologne, Germany; Private Practice, Münster, Germany.

⁵Associate Professor, Department of Oral and Maxillofacial Plastic Surgery, University of Frankfurt, Frankfurt, Germany; Private Practice, Forchheim, Germany.

⁶Professor and Head, Department of Periodontology, Julius-Maximilians-University, Würzburg, Germany.

⁷Associate Professor, Department of Periodontology, Operative and Preventive Dentistry, University of Bonn, Bonn, Germany.

Correspondence to: Priv-Doz Dr Stefan Fickl, Department of Periodontology, University of Würzburg, Pleicherwall 2, 97070 Würzburg, Germany.
 Email: fickl_s@ukw.de

©2017 by Quintessenz Publishing Co Inc.

In 2003, Schropp et al¹ evaluated 46 extraction sites in the maxillary and mandibular posterior areas and demonstrated shrinkage in the buccolingual bone width of 50% after 12 months. Remarkably, two-thirds of this change was witnessed at the buccal aspect. Furthermore, the bone height decreased by 0.8 mm 3 months after tooth extraction. A recent review article confirmed that tooth extraction leads to horizontal bone loss of 29% to 63% and vertical bone loss of 11% to 22% after 6 months.²

A variety of studies have evaluated the effect of ridge preservation techniques on the resorption process of the extraction socket. Among them, the present group showed in a series of preclinical and clinical studies that ridge preservation techniques are capable of reducing dimensional alterations but fail to preserve the extraction socket.^{3–8} Most recently, Vignoletti et al⁹ presented a review article and confirmed that alveolar ridge preservation resulted in significantly less vertical and horizontal contraction of the alveolar bone crest when compared to spontaneous healing. The subgroup analysis revealed that the use of barrier membranes, a flap surgical procedure, and a full flap closure demonstrated better results. The authors, however, stress that no clear guidelines are provided

regarding the type of biomaterial or surgical procedure. Another recent review article reports that in addition to the general beneficial effect of alveolar ridge preservation, flap elevation, use of a membrane, and application of a xenograft or an allograft are associated with superior outcomes.¹⁰

Horváth et al¹¹ presented a systematic review regarding the effect of alveolar ridge preservation and concluded that ridge preservation limits the postextraction resorption process but is not capable of entirely avoiding ridge atrophy. The authors also found evidence that alveolar ridge preservation might not always promote new bone formation. This is in agreement with an experimental animal study reporting that placement of biomaterial in the fresh extraction socket retards the healing process in comparison with spontaneous socket healing.¹²

Subsequently, the present authors primarily sought to assess the quantitative alveolar ridge changes after different alveolar ridge preservation techniques using the measurement method implied in a landmark study¹ of extraction socket management.

Materials and Methods

This paper was prepared following the Consolidated Standards of Reporting Trials (CONSORT) guidelines.

Study Design

This study was planned and performed as a single-center prospective randomized controlled clinical trial.

Participants

Subjects were recruited by independent examiners from the patient population of the Julius-Maximilians-University, Würzburg, Germany. Each subject gave written informed consent after thorough explanation of the nature, risks, and benefits of the clinical investigation and associated procedures. The University's Ethical Committee approved the consent form and experimental protocol on October 31, 2011 (183/11).

The following exclusion criteria were applied:

- Aged < 18 years
- Uncontrolled, manifest diabetes mellitus (based on patient self-report)
- Radiation, chemotherapy, or intravenous bisphosphonates within the last 5 years (based on patient self-report)
- Infectious diseases (HIV, hepatitis B or C) (based on patient self-report)
- Pregnant or lactating (based on patient self-report)
- Heavy smoker (> 10 cigarettes/day) (based on patient self-report)
- Multiple neighboring extraction sites

- Untreated periodontal disease (probing depths \geq 4 mm in more than five sites)

Teeth with deficient buccal bone plates were not excluded in this trial. The investigation was entirely carried out in the Department of Periodontology of the Julius-Maximilians-University, Würzburg.

Interventions

All subjects received oral hygiene instructions and, if needed, a dental cleaning of plaque and calculus. In addition, participants were instructed to rinse with 0.2% chlorhexidine digluconate three times per day starting 4 days before tooth extraction. Preoperative or postoperative antibiotic therapy was not used in this trial.

Before tooth removal and 6 months postoperative, silicone impressions (Identium, Kettenbach) were obtained for stone cast measurements.

Five different surgeons, all trained in periodontology and implant dentistry, performed tooth extraction. After local anesthesia (4% articaine with 1:100,000 epinephrine), the tooth was removed without flap elevation and as atraumatically as possible without harming the bony walls. Thereafter, the alveolus was randomly allocated to one of the following treatment modalities:

- Control: Socket was left to blood clot formation without any further treatment

Fig 1 (left) Clinical situation with hopeless maxillary second premolar.

Fig 2 (right) Tooth extraction and ridge preservation using DBBM and collagen membrane (Tx3).

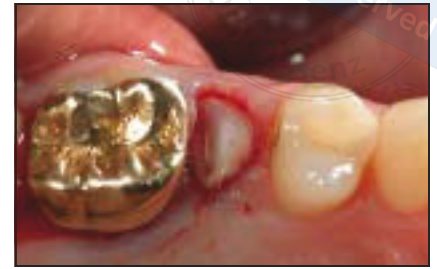
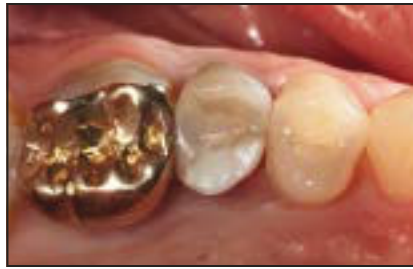
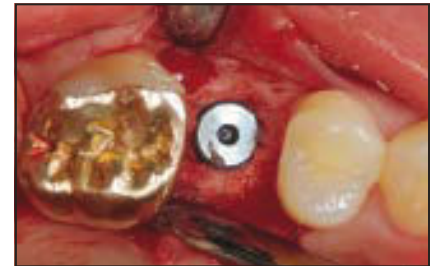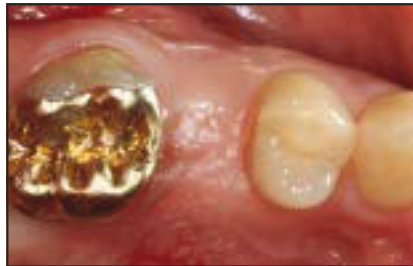Fig 3 (left) Clinical situation 6 months postoperative.

Fig 4 (right) Intraoperative situation with implant placed.



- Tx1: Application of a demineralized bovine bone mineral (DBBM) substitute to the level of the bony crest (Endobon, Zimmer Biomet) and socket closure with a soft tissue punch from the palate with interrupted sutures (Seralene 6-0, Serag Wiesner)
- Tx2: Identical treatment to the Tx1 group without application of a soft tissue punch
- Tx3: An adsorbable collagen membrane (Osseoguard, Zimmer Biomet) was adapted to the internal part of the buccal bone plate, the socket was filled with DBBM, and the membrane was folded to cover the bone substitute and fixed to the lingual soft tissues with adsorbable sutures (Serafit 6-0, Serag Wiesner) (Figs 1 and 2)

The patients were instructed to rinse with 0.2% chlorhexidine digluconate three times a day for at least

2 weeks. As an antiphlogistic medication, ibuprofen (600 mg) was prescribed when needed. Sutures were removed 7 days after surgery.

The patients were scheduled for implant surgery 6 months after tooth extraction (Figs 3 and 4). Following flap reflection, bone density (D1 to D4) and need for reaugmentation were assessed by the surgeon and recorded.

Biomaterials Used

Osseoguard barriers consist of type I bovine Achilles tendon collagen derived from closed New Zealand herds. Studies have shown that this biomaterial can facilitate bone regeneration with or without additional biomaterial.¹³ Endobon is a bovine-derived, deproteinized, osteoconductive hydroxyapatite ceramic. For ridge preservation procedures in particular, this material has been shown to be effective to foster consecutive implant placement.¹⁴

Objectives

The primary objective of this clinical trial was to compare horizontal and vertical tissue loss following different alveolar ridge preservation techniques. In addition, clinically relevant factors such as bone density and need for reaugmentation were evaluated.

Outcomes

The primary outcome variable was buccolingual tissue atrophy assessed on stone cast models. Secondary outcomes included buccal and lingual midfacial tissue loss, need for reaugmentation, and bone quality. Need for reaugmentation was assessed with a yes/no query to the surgeon after implant surgery. Bone quality was subjectively assessed by the surgeon following initial drilling for the implant osteotomy using the classification (D1 to D4) of Lekholm et al.¹⁵

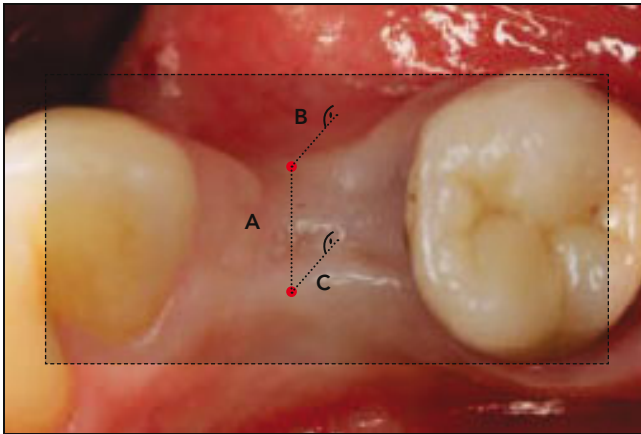


Fig 5 Schematic drawing of the performed measurements according to Schropp et al.¹ A straight plane was used to connect the occlusal surfaces. The distance from this plane to the most occlusally situated point from both the buccal (B) and the oral (C) side was calculated. Additionally, the width of the alveolar ridge was recorded when connecting the two points on the buccal and lingual aspects (A).

Randomization

Randomization was performed using a computerized randomization scheme (SPSS version 16, IBM) and communicated to the surgeon directly following tooth extraction.

Blinding

The implant surgeon, evaluating secondary outcomes bone density and need for reaugmentation, was blinded to the initial treatment. Both examiners of the stone cast models were blinded to the allocated extraction socket treatment.

Stone Cast Measurements

Casts were prepared from irreversible silicone impressions taken at the time of tooth extraction and at 6 months postoperative. Stone cast measurements were performed according to Schropp et al.¹ After thorough reading of the article and personal communication with

the first author, the measurement procedure was performed by two examiners blinded to the allocated treatments (Fig 5). The occlusal surfaces of the adjacent teeth were connected with a straight plane. The distance from the midpoint of the extraction site perpendicular to this line was recorded at the most occlusally situated point, from the buccal and oral perspectives. Additionally, the width of the alveolar ridge was recorded when connecting the two points on the buccal and lingual aspect. The measurements were carried out by two blinded examiners (N.P. and K.F.). Agreement between the two investigators was assessed by calculating Kendall tau using the `cor.test()` function.

Statistical Analysis

All statistics were done using R version 3.1.1. Loss of tissue was quantified by subtracting the mean of the postoperative measurements from the mean of the preoperative measurements. Normal distribution

of the resulting data points was assessed using histograms. Data for the primary outcome (buccolingual horizontal dimension loss) and the two secondary outcomes (midbuccal and midlingual vertical dimension loss) were visualized using `ggplot2()` and analyzed using standard multiple regression using the `lm()` function in R. Continuous measurements for the three outcome variables were modeled as the dependent variable, and the four-factor variable treatment (control, T1, T2, T3), the three-factor variable tooth type (anterior, premolar, molar), the two-factor variable jaw (maxilla, mandible), the two-factor variable sex (men, women), the five-factor variable surgeon, and the five-factor variable reason for extraction (endodontic, endo/perio, fracture, decay, perio) were modeled as independent variables. Interaction terms for treatment, tooth type, and jaw were added to the model. Stepwise backward model selection was performed based on the Akaike information criterion using the `stepAIC()` function in the MASS package 7.3-33.

Results

Participant Flow

The study population consisted of 40 patients (24 women and 16 men) aged 18 to 80 years (mean age 55.7 \pm 14.85 years) with one or more hopeless teeth with intact neighboring teeth. All 40 patients enrolled in the study underwent either alveolar ridge preservation (Tx1, Tx2, or Tx3) or were allocated to the control group. Of these, 35 patients completed the study and complied with all study appointments. There were five dropouts due to noncompliance with the study protocol ($n = 3$) or refraining from implant placement ($n = 2$). There was no significant intergroup difference in baseline patient characteristics with respect to age ($P > .01$).

Primary and Secondary Outcomes

Excellent agreement (Kendall rank correlation tau = 0.97, $P < 2.2 \times 10^{16}$) was found between the two investigators of stone cast models.

After adjusting for tooth type, jaw, patient sex, surgeon, and reason for the extraction, treatments Tx1 and Tx3 resulted in significantly less buccolingual dimension loss (Tx1: 2.3 \pm 0.9 mm improvement, $P = .016$; Tx3: 2.9 \pm 0.7 mm improvement, $P = .0007$) (Table 1, Fig 6). In comparison to anterior teeth, the treatment of premolars led to significantly reduced dimensional loss (2.0 \pm 0.8 mm improvement, $P = .03$). In comparison to teeth extracted for

Table 1 Coefficients for the Multiple Regression Solution for Loss of Buccolingual Width

	Estimate	SE	P
(Intercept)	3.32	0.51	.00001
Tx1	-2.31	0.85	.0159
Tx2	1.20	0.86	.1855
Tx3	-2.88	0.67	.0007
Molar	-1.03	0.68	.1508
Premolar	-1.95	0.82	.0308
Maxilla	0.20	0.72	.7829
Female	0.68	0.29	.0313
Extraction due to endo/perio	-0.34	0.49	.4992
Extraction due to fracture	-0.48	0.22	.0447
Extraction due to decay	-0.54	0.86	.5421
Extraction due to perio	-0.12	0.35	.7334
Tx1, premolar	2.38	0.96	.0249
Tx3, premolar	2.24	1.02	.0443
Tx2, maxilla	-1.56	0.88	.972
Tx3, maxilla	0.17	0.80	.8344

Width loss was modeled as a function of treatment, tooth type, jaw, sex, surgeon (data not shown), and extraction reason. An interaction of treatment and tooth type as well as jaw improved the model significantly. Data are presented for the optimal model based on AIC. Adjusted $r^2 = 0.7719$, P value for the model = .00019.

endodontic reasons, extraction of teeth due to fracture reduced the dimensional loss (0.5 \pm 0.2 mm, $P = .04$). There was significant interaction between treatment and tooth type.

For the secondary outcomes, no significant models could be fitted, indicating very similar outcomes.

No adverse events were reported.

Discussion

In this randomized controlled clinical trial, an attempt was made to

identify whether different alveolar ridge preservation techniques using a bovine xenograft to fill the extraction socket reduce contour changes after tooth extraction and whether these procedures facilitate implant placement and reduce further need for bone augmentation. It was demonstrated that alveolar ridge preservation using a bovine xenograft and either a soft tissue graft from the palate or a collagen barrier membrane to close the socket orifice led to significantly less bucco-oral contour change when compared to spontaneous socket healing or socket grafting alone. No significant

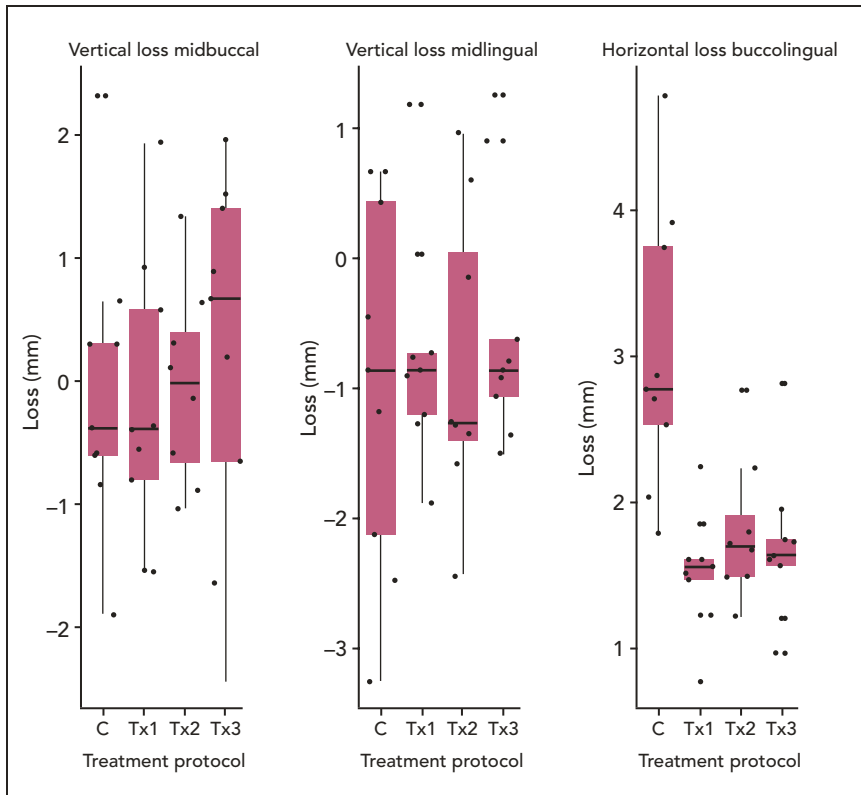


Fig 6 Box plots for the primary outcome variable horizontal loss and the secondary outcomes buccal and lingual vertical loss. C = control.

differences could be assessed for secondary outcomes such as need for reaugmentation or bone quality. Teeth extracted due to fracture and premolar teeth showed significantly less dimensional loss regardless of the applied therapy.

Ridge preservation has been described to counteract bone loss after tooth extraction,^{14,16} although bone remodeling after tooth extraction is not completely avoidable.^{5,7} The results of the present study are consistent with these findings and confirm all recent review articles demonstrating that alveolar ridge preservation leads to less tissue contraction when compared to spontaneous socket healing.^{9,17,18}

More specifically, the findings that closing the orifice of the socket with either a soft tissue punch or an adsorbable barrier membrane seems to be beneficial for ridge preservation in the horizontal dimension is in agreement with previous studies. Vittorini Orgeas et al¹⁸ showed in a systematic review that when the selected studies were divided into three groups, it was demonstrated that barrier alone produces better clinical results than graft and barrier or graft alone. The authors argue that the protective effect of the barrier has a space-making effect and shields the blood clot. In another review article, it was also demonstrated that besides a con-

siderable heterogeneity, guided bone regeneration procedures using barrier membranes appeared to be most effective for ridge preservation.¹¹ Furthermore, Mardas et al¹⁹ detected new bone formation and reduced bone loss after the application of a biphasic synthetic biomaterial or a bovine DBBM with a barrier membrane after 8 months. In 2008, Wang and Tsao²⁰ showed histomorphometrically a high percentage of vital bone (68.5%) with minimal residual allograft particles (3.8%). Moreover, Perelman-Karmon et al²¹ reported a higher percentage of new bone formation after DBBM/collagen barrier membrane compared to DBBM alone, increasing from apical to coronal (47% vs 36.3% and 35.2% vs 22.8%).

In this study, the collagen membrane was intentionally left uncovered. Some authors have demonstrated that membrane exposure to the oral cavity might cause bacterial penetration and thus lower the quality of attainable bone regeneration.²² On the contrary, more recent studies revealed that secondary wound healing with membrane exposure does not seem to jeopardize socket regeneration.^{23,24}

The results of the present study also suggest that sealing the augmented socket with a punch graft from the palate is able to significantly limit the bucco-oral shrinkage compared to grafting alone or spontaneous healing. Additional soft tissue augmentation or socket-seal surgery seem beneficial to reduce ridge contour changes or soft tissue collapse.⁷ However, a recent consensus statement remained indecisive

concerning this additional procedure,²⁵ which requires a second surgical site with higher postoperative morbidity that has to be weighed against the expected advantage. Nevertheless, the lowest volumetric changes were reported after the application of a palatal punch with or without bone grafting.⁸ After 4 months of healing, significantly less volumetric shrinkage was found compared to untreated control sites ($-0.79/-0.85$ vs -2.29), however, there was no difference between the group using a soft tissue punch and the group solely using socket filling with a bone substitute.

Deficient buccal bone plates were not excluded in the present trial. This can be seen as a limitation, as standardization of the extraction sockets might vary using this approach. On the other hand, Lee et al²⁶ demonstrated in a review article that tissue atrophy of intact extraction sockets (where immediate implants have been placed) is significantly less when compared to the values described in reviews for postextraction alveolar soft and hard tissue changes.² As a consequence, it might be speculated that extraction sockets with deficient buccal bone plates would benefit more from ridge preservation. Thus, these sockets were included in the present study.

Conclusions

Within the limits of the present trial (limited number of studied patients, two-dimensional assessment on stone cast models, preopera-

tive assessment of ridge contour as baseline measurement), it may be concluded that ridge preservation can limit bucco-oral tissue shrinkage, particularly when a barrier membrane or soft tissue punch is used to close the socket orifice. On the other hand, percentage of implant osseointegration or bone density and need for reaugmentation were not significantly different among the treatment groups. This implies that the overall clinical benefit of ridge preservation techniques is still unclear, particularly in the esthetic zone. However, as this is only a 6-month observation, it might be interesting to witness tissue alterations over time in different treatment groups with the final prosthetic restoration in place (ie, tissue recession, prosthetic complications).

Acknowledgments

The authors M.K., A.H., M.S., and N.P. reported no conflicts of interest related to this study. S.F. and K.F. have a financial relationship with Zimmer Biomet resulting from research funding and speaking engagements. The study was supported by a grant from Zimmer Biomet.

References

- Schropp L, Wenzel A, Kostopoulos L, Karring T. Bone healing and soft tissue contour changes following single-tooth extraction: A clinical and radiographic 12-month prospective study. *Int J Periodontics Restorative Dent* 2003;23:313–323.
- Tan WL, Wong TL, Wong MC, Lang NP. A systematic review of post-extraction alveolar hard and soft tissue dimensional changes in humans. *Clin Oral Implants Res* 2012;23(suppl):s1–s21.
- Fickl S, Schneider D, Zuhr O, et al. Dimensional changes of the ridge contour after socket preservation and buccal overbuilding: An animal study. *J Clin Periodontol* 2009;36:442–448.
- Fickl S, Zuhr O, Wachtel H, Bolz W, Huerzeler M. Tissue alterations after tooth extraction with and without surgical trauma: A volumetric study in the beagle dog. *J Clin Periodontol* 2008;35:356–363.
- Fickl S, Zuhr O, Wachtel H, Bolz W, Huerzeler MB. Hard tissue alterations after socket preservation: An experimental study in the beagle dog. *Clin Oral Implants Res* 2008;19:1111–1118.
- Fickl S, Zuhr O, Wachtel H, Kebschull M, Hürzeler MB. Hard tissue alterations after socket preservation with additional buccal overbuilding: A study in the beagle dog. *J Clin Periodontol* 2009;36:898–904.
- Fickl S, Zuhr O, Wachtel H, Stappert CF, Stein JM, Hürzeler MB. Dimensional changes of the alveolar ridge contour after different socket preservation techniques. *J Clin Periodontol* 2008;35:906–913.
- Thalmair T, Fickl S, Schneider D, Hinze M, Wachtel H. Dimensional alterations of extraction sites after different alveolar ridge preservation techniques: A volumetric study. *J Clin Periodontol* 2013;40:721–727.
- Vignoletti F, Matesanz P, Rodrigo D, Figuero E, Martin C, Sanz M. Surgical protocols for ridge preservation after tooth extraction. A systematic review. *Clin Oral Implants Res* 2012;23(suppl):s22–s38.
- Avila-Ortiz G, Elangovan S, Kramer KW, Blanchette D, Dawson DV. Effect of alveolar ridge preservation after tooth extraction: A systematic review and meta-analysis. *J Dent Res* 2014;93:950–958.
- Horváth A, Mardas N, Mezzomo LA, Needleman IG, Donos N. Alveolar ridge preservation. A systematic review. *Clin Oral Investig* 2013;17:341–363.
- Lindhe J, Cecchinato D, Donati M, Tomasi C, Liljenberg B. Ridge preservation with the use of deproteinized bovine bone mineral. *Clin Oral Implants Res* 2014;25:786–790.
- De Angelis N, Felice P, Pellegrino G, Camurati A, Gambino P, Esposito M. Guided bone regeneration with and without a bone substitute at single post-extractive implants: 1-year post-loading results from a pragmatic multicentre randomised controlled trial. *Eur J Oral Implantol* 2011;4:313–325.

14. Barone A, Todisco M, Ludovichetti M, et al. A prospective, randomized, controlled, multicenter evaluation of extraction socket preservation comparing two bovine xenografts: Clinical and histologic outcomes. *Int J Periodontics Restorative Dent* 2013;33:795–802.
15. Lekholm U, Zarb G, Albrektsson T. Patient selection and preparation. In: Brånemark PI, Zarb GA, Albrektsson T (eds). *Tissue Integrated Prostheses: Osseointegration in Clinical Dentistry*. Chicago: Quintessence, 1985:199–209.
16. Barone A, Ricci M, Tonelli P, Santini S, Covani U. Tissue changes of extraction sockets in humans: A comparison of spontaneous healing vs. ridge preservation with secondary soft tissue healing. *Clin Oral Implants Res* 2013;24:1231–1237.
17. Ten Heggeler JM, Slot DE, Van der Weijden GA. Effect of socket preservation therapies following tooth extraction in non-molar regions in humans: A systematic review. *Clin Oral Implants Res* 2011;22:779–788.
18. Vittorini Orgeas G, Clementini M, De Risi V, de Sanctis M. Surgical techniques for alveolar socket preservation: A systematic review. *Int J Oral Maxillofac Implants* 2013;28:1049–1061.
19. Mardas N, Chadha V, Donos N. Alveolar ridge preservation with guided bone regeneration and a synthetic bone substitute or a bovine-derived xenograft: A randomized, controlled clinical trial. *Clin Oral Implants Res* 2010;21:688–698.
20. Wang HL, Tsao YP. Histologic evaluation of socket augmentation with mineralized human allograft. *Int J Periodontics Restorative Dent* 2008;28:231–237.
21. Perelman-Karmon M, Kozlovsky A, Liloy R, Artzi Z. Socket site preservation using bovine bone mineral with and without a bioresorbable collagen membrane. *Int J Periodontics Restorative Dent* 2012;32:459–465.
22. Engler-Hamm D, Cheung WS, Yen A, Stark PC, Griffin T. Ridge preservation using a composite bone graft and a bioabsorbable membrane with and without primary wound closure: A comparative clinical trial. *J Periodontol* 2011;82:377–387.
23. Barone A, Borgia V, Covani U, Ricci M, Piatelli A, Iezzi G. Flap versus flapless procedure for ridge preservation in alveolar extraction sockets: A histological evaluation in a randomized clinical trial. *Clin Oral Implants Res* 2015;26:806–813.
24. Cardaropoli D, Cardaropoli G. Preservation of the postextraction alveolar ridge: A clinical and histologic study. *Int J Periodontics Restorative Dent* 2008;28:469–477.
25. Wang RE, Lang NP. Ridge preservation after tooth extraction. *Clin Oral Implants Res* 2012;23(suppl):s147–s156.
26. Lee CT, Chiu TS, Chuang SK, Tarnow D, Stoupe J. Alterations of the bone dimension following immediate implant placement into extraction socket: Systematic review and meta-analysis. *J Clin Periodontol* 2014;41:914–926.